



## Summary Feedback

(Combined feedback broadcasted multiple time this week)

### **PRE-RECORDED: Basildon FRCR 2B 'A to Zee' Course 2020**

## **Session 1/36**

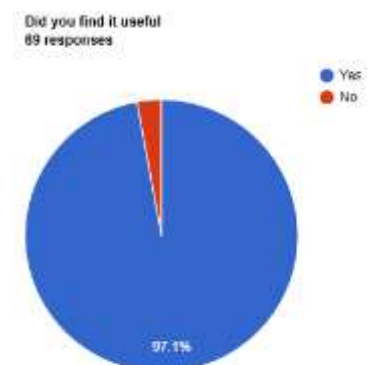
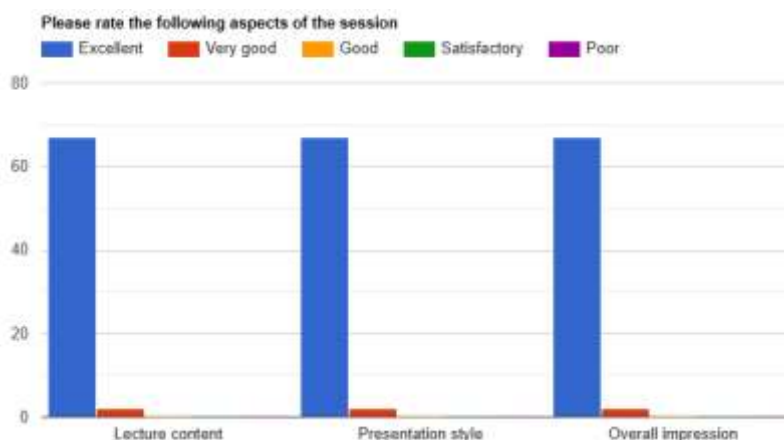
### **CHEST X-RAY FOR FRCR EXAM PART-1**

**(17<sup>th</sup> & 18<sup>th</sup> January 2026)**

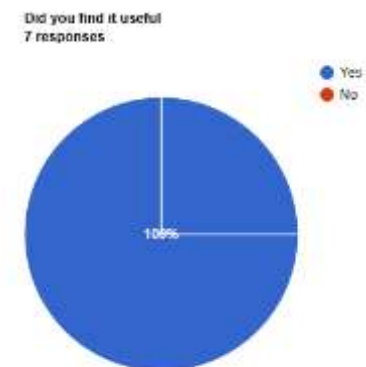
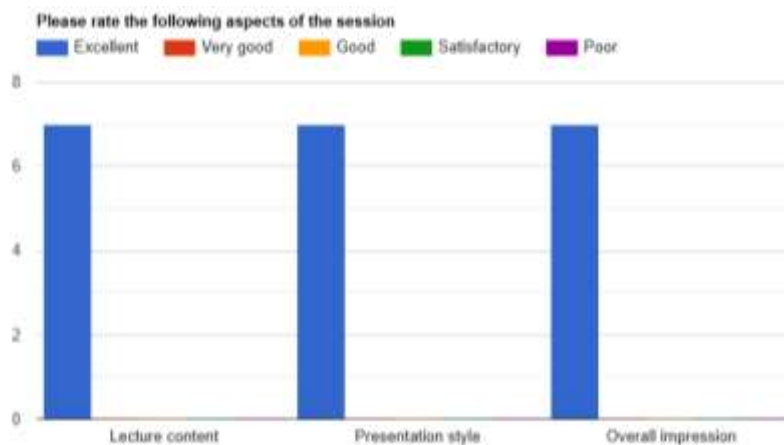
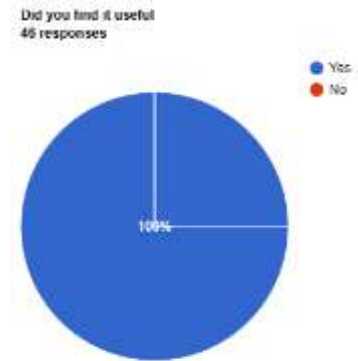
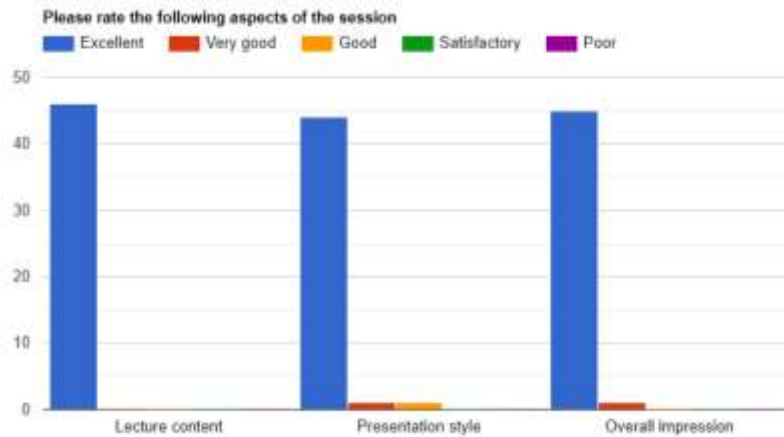
**Lecturer: Thaj Rehman**

#### **Summary Points:**

- Total Attendees: 359 from 34 Countries (Algeria, Austria, Bahamas, Bangladesh, CAR, Egypt, Ghana, Hong Kong, India, Indonesia, Iraq, Jordan, Kenya, Libya, Malawi, Malaysia, Maldives, Malta, Nepal, Nigeria, Oman, Pakistan, Saudi Arabia, South Africa, Sri Lanka, Sudan, Thailand, Türkiye, UAE, Uganda, UK, Yemen, Zambia, Zimbabwe).
- Total duration: 2.5 hours (each session broadcasted thrice during the week)
- Total feedback received from 122 participants, from three different broadcasts



## CHEST X-RAY FOR FRCR EXAM PART-1



### Testimonials

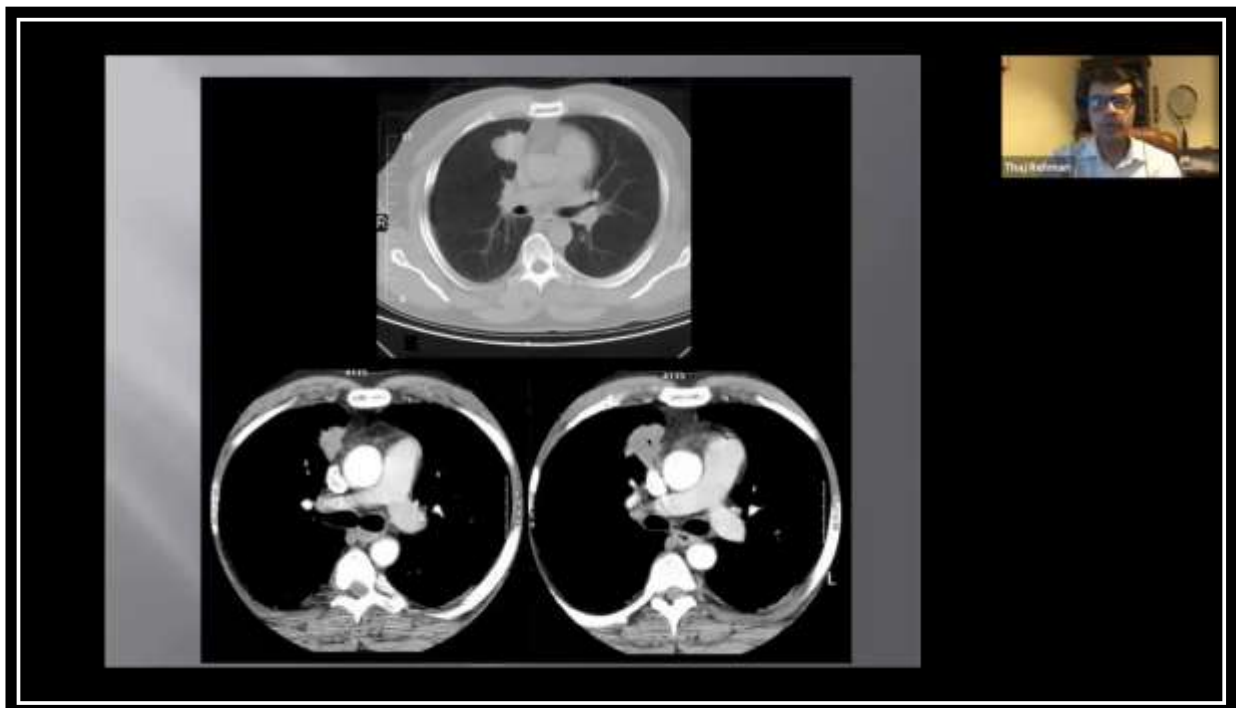
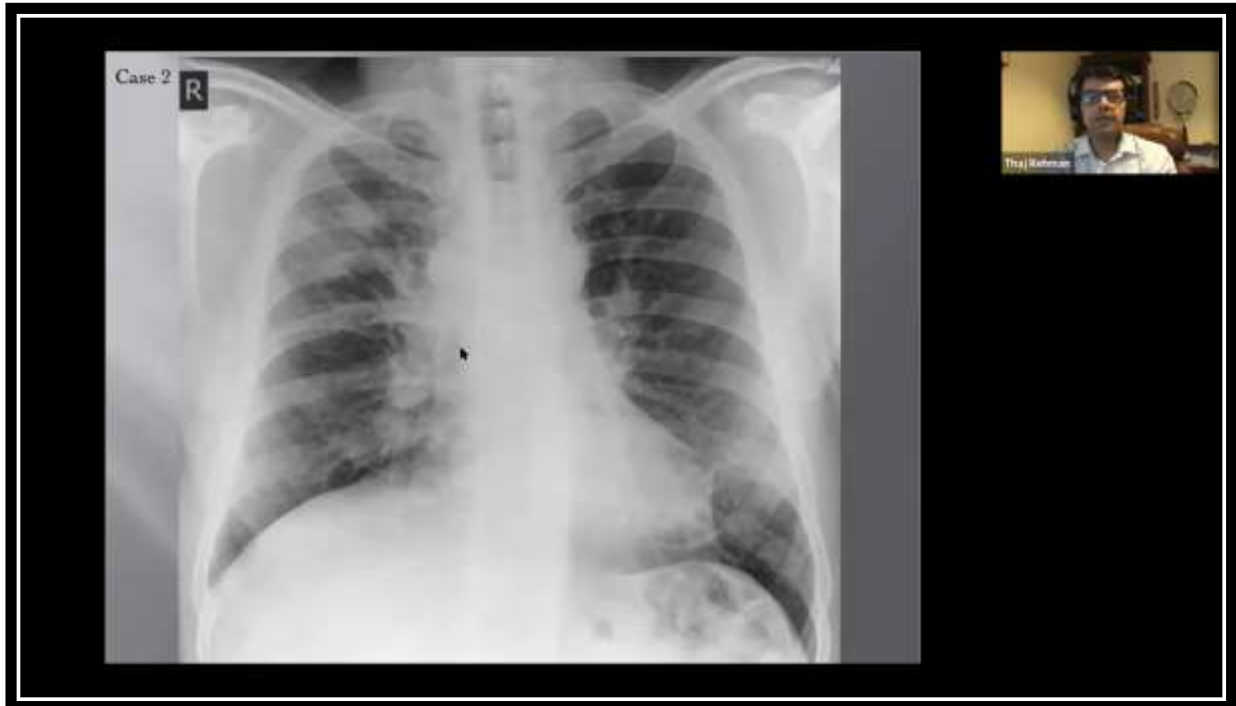
- The lecture was very nice. Easy presentation and good explanation for important topics. Thank you for your effort (Jordan).
- Repeating this brilliant session, it is very useful to do, as it helps consolidate important signs and important pattern recognition when dealing with plain chest films (Egypt).
- Case discussion followed with a brief review of theory and explanation; constructive feedback was useful. Cream of the cream of X-ray thorax (Algeria).
- The whole lecture was very helpful for me. It covers the main topics in chest radiography, especially lung collapse and its related causes (Jordan).
- Excellent lecture of chest cases with changed 2B pattern of more inclusion of plain films. It is a very good lecture to detect abnormalities (Saudi Arabia).
- As always, a brilliant session with a wide range of cases. Thank you (Nepal).
- Useful revision. Well-selected cases and points to differentiate DD (UK).
- Going into detail about the DDX, explaining the spine sign, hilum overlay, etc., and exam tips were useful (Kenya).
- A well-planned teaching session with loads of scaffolding and candidate support (UK).
- Brilliant session (UAE).

## CHEST X-RAY FOR FRCR EXAM PART-1

- The variety of cases and feedback was useful (Malaysia).
- Very good session. Great learning. Thank you very much (Pakistan).
- The clear explanation of each case was useful (Thailand).
- Case presentation was useful (Bahamas).
- Chest radiograph opacities were useful (UK).
- Real-time exam scenarios are really helping out (India).
- Every aspect of the session was useful (Nigeria).
- Typical chest X-rays used for the teaching were useful (Saudi Arabia).
- Going through all the cases and having some slides dedicated to teaching was useful (UK).
- Multiple findings in a single film helping to reach the diagnosis were useful (India).
- Excellent teaching session (Nigeria).
- Great session (Libya).
- Nice and fantastic chest X-ray cases were useful (Sudan).
- Multiple cases and covering every pathology were useful (Libya).
- Correlation of one finding to other subtle findings was useful (Pakistan).
- Great learning. Thank you very much (Pakistan).
- Case discussions between teacher and candidates were useful (Pakistan).
- All aspects are perfect (Saudi Arabia).
- A variety of cases with excellent explanations to reach proper diagnoses were useful (Pakistan).
- Great comprehensive lecture (Pakistan).
- Almost all chest X-ray pathologies quickly covered (CAR).
- Interesting cases and teaching points (India).
- Every single aspect was useful (UK).
- Very well-presented sessions. Very helpful (Pakistan).
- Very good (UAE).
- The variety of cases and summary slides was useful (UK).
- The case discussions were useful (India).
- Too many radiographs were shown, and how not to miss nodules was useful (Pakistan).
- Comprehensive lecture! (UK).
- The variety, the explanation, everything was useful (Pakistan).
- Good cases (UK).
- Good exposure to X-rays was useful (India).
- Very subtle and important cases (UK).
- The pattern of approach and correlation was useful (Oman).
- Collection of cases was very good (Saudi Arabia).
- Amazing session (Pakistan).
- Grateful to presenter and team (UK).
- Excellent description (Nigeria).
- It's all useful (UAE).
- All of it was useful (Sudan).
- Everything was useful (UK).
- Excellent teaching (India).
- Content and delivery were useful (UK).
- The X-rays with subtle findings were useful (Pakistan).
- Fantastic cases (UK).
- Good cases and teaching (UK).
- Excellent cases and very informative (India).

## CHEST X-RAY FOR FRCR EXAM PART-1

- It was perfect (UAE).
- Interesting cases (UK).
- Variety of cases was useful (India).
- Cases and teaching were useful (Saudi Arabia).
- Exam-oriented session (India).



=====XX=====XX=====